

Dry Eye in Ovariectomized Cynomolgus Monkeys - A 54 Months Follow-up Study

Qin Liao, Zhaohui Yan, Zhijia Li, Keyang Cai, DanDan Lu, Niqiong Ge, Byron H. Li

Joinn Laboratories (Suzhou) Inc. Taichang, Jiangsu, 215421, China

Corresponding author:
liheping@joinn-lab.com

Introduction

To investigate the feasibility of ovariectomized Cynomolgus monkey as an animal model of postmenopausal dry eye.

Animals and Methods

Six healthy adult female monkeys, age 4-6 years, body weight 3.0-3.8 kg, were randomly divided into two groups (n=3/group). Bilateral ovariectomy or a sham procedure was performed in the animals in experimental or control group, respectively. The level of estradiol and testosterone in serum was measured at month (M) 0, 1, 3, 6, 12, 17, 23, 52 and 54 post surgical procedures. The tear production, tear osmotic pressure, corneal fluorescein staining were performed every 1-7 months during the 54 months follow up observations. Conjunctival impression cytology was conducted at M 6, 23, and 54 and imaging of meibomian glands was performed at M54.

Results

Compared with control group, the serum level of estradiol and testosterone in experimental group decreased at each time point of testing (**Figure 1 & 2**). The estradiol decreased significantly ($p < 0.05$) at M 3, 17, 23, 52 and so did testosterone at M 6, 9, and 39, respectively. In the experimental group, the relative tear production rate decreased in a range of 6.9%-71.4% and the relative tear osmotic pressure elevated in the range of 11.9%-30.4% in most of the time points (**Figure 3 & 4**). Started from M23, the eyes of experimental monkeys showed positive corneal fluorescein staining and the scores were significantly higher than that of sham group (2.2 ± 1.5 vs. 0 ± 0 , $p \leq 0.05$) at M26, and remained higher even if not significant than that of sham group ($p > 0.05$) in all time points (**Figure 5**). In experimental animals, the conjunctival impression cytology indicated representative pathological changes such as decreased number of goblet cells and grade III Nelson's change in most of the conjunctival epithelial cells since M23 (**Figure 6**); the meibomian gland deletion score was higher than that of control group 54 months after the surgery (**Figure 7 & 8**).

Conclusions

The changing trend of sex hormone level and ocular characterizations of dry eye in overietomized monkeys was similar to that of postmenopausal women, which revealed the utility of this model in mechanisms and therapeutic studies of menopausal.

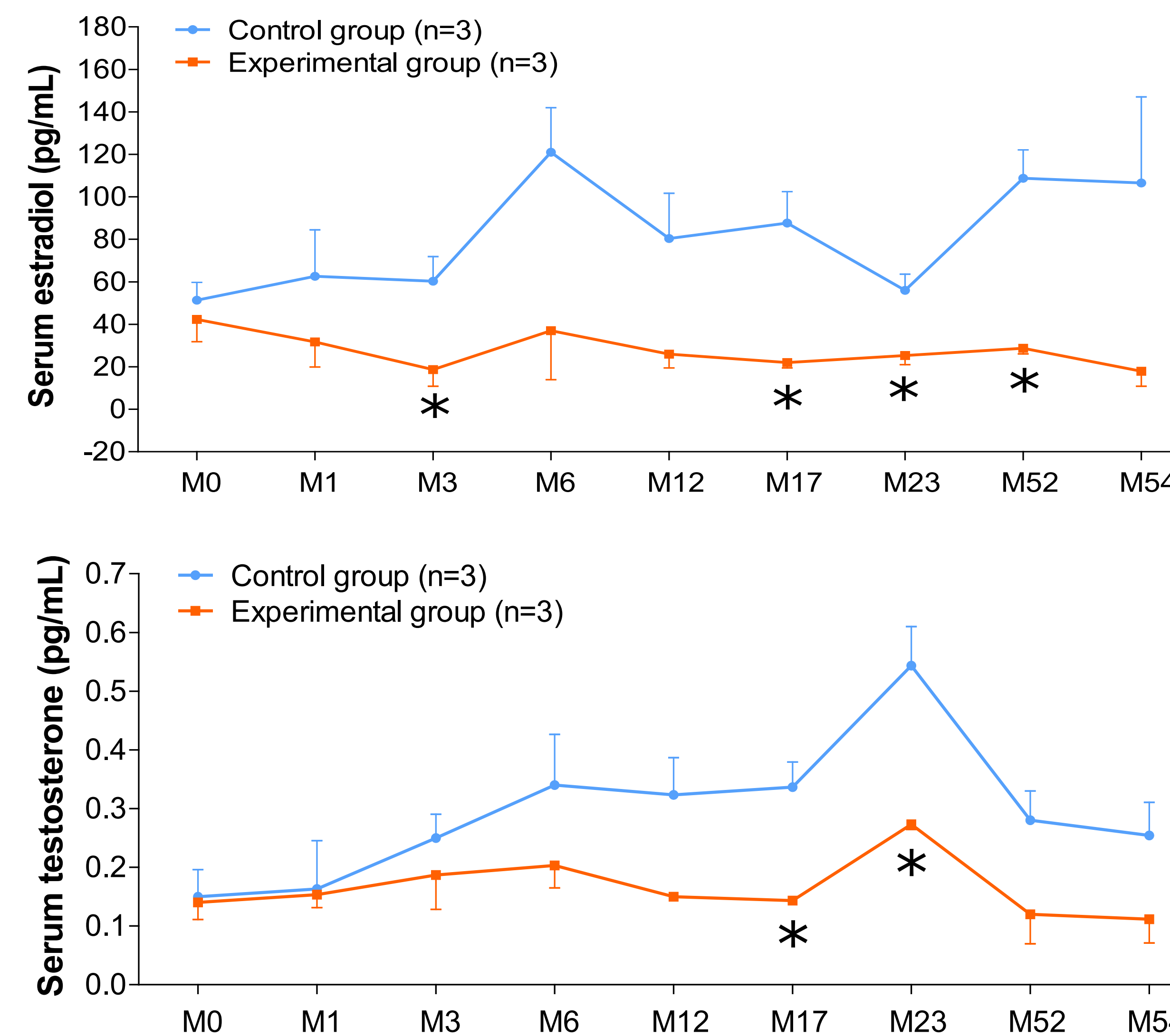


Figure 1 (upper) & 2 (lower). The serum level of estradiol and testosterone in experimental group decreased at each time point of testing compared with control group. The estradiol decreased significantly ($p < 0.05$) at M 3, 17, 23, 52 and so did testosterone at M 6, 9, and 39, respectively. (Mean \pm SEM)

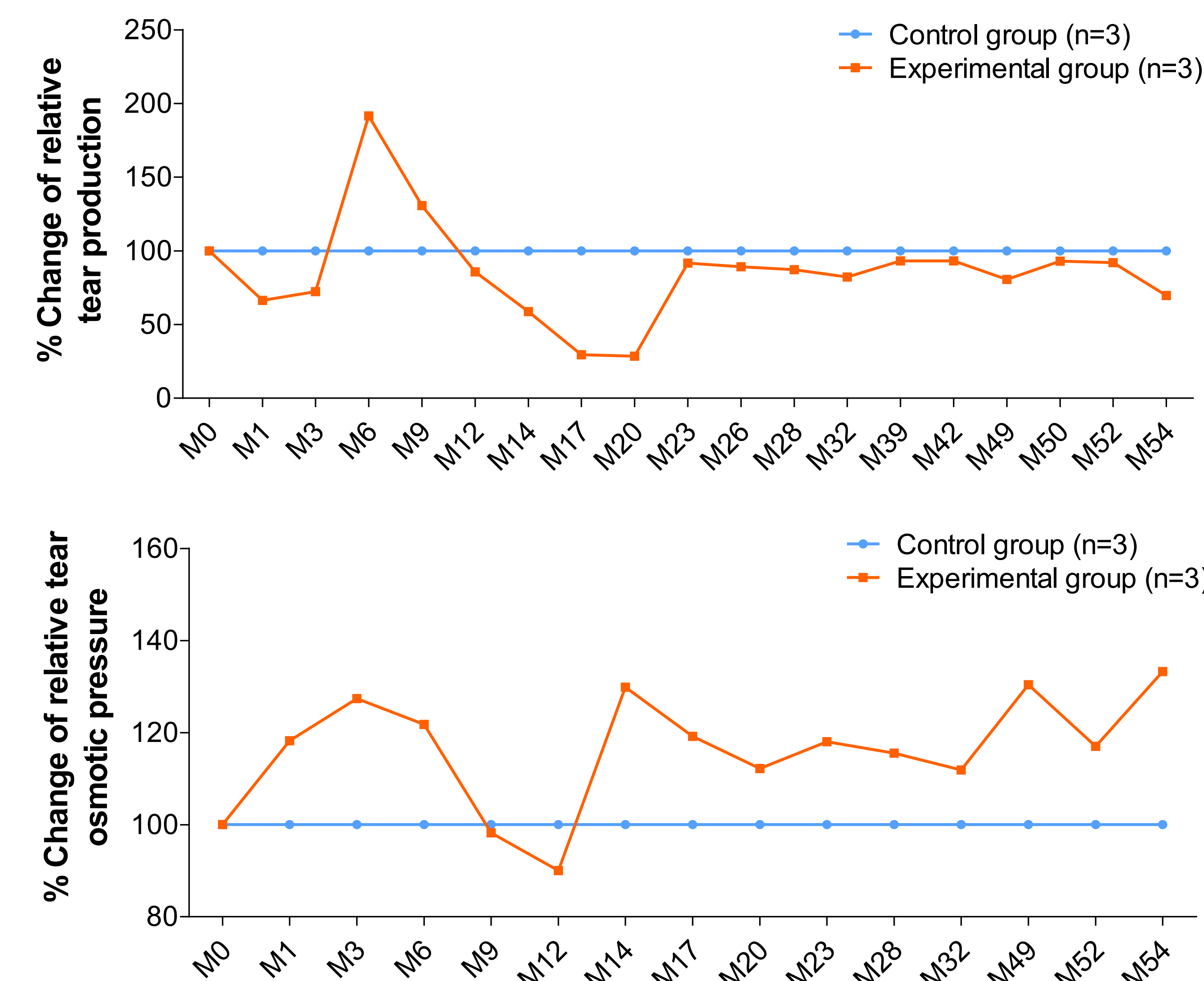


Figure 3 (upper) & 4 (lower). In the experimental group, the relative tear production rate decreased in a range of 6.9%-71.4% and the relative tear osmotic pressure elevated in the range of 11.9%-30.4% in most of the time points.

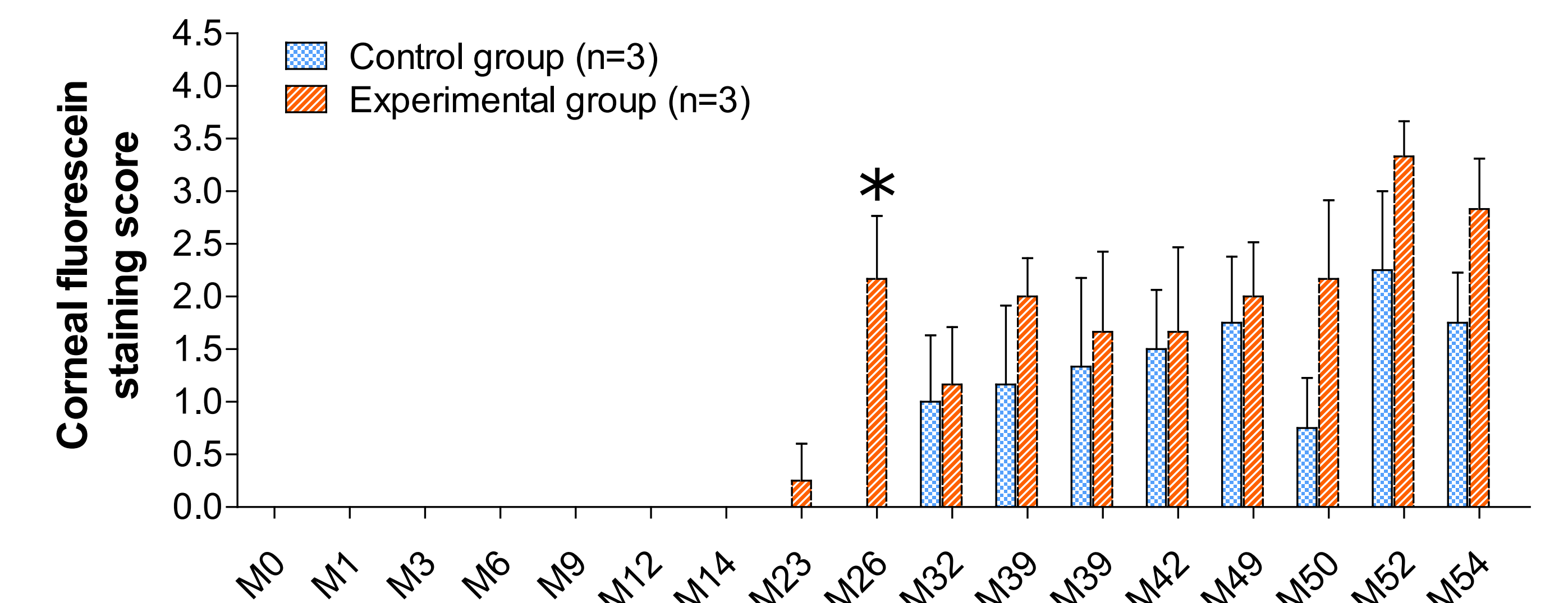


Figure 5. Started from M23, the eyes of experimental monkeys showed positive corneal fluorescein staining and the scores were significantly higher than that of sham group (2.2 ± 1.5 vs. 0 ± 0 , $p \leq 0.05$) at M26, and remained higher even if not significant than that of sham group ($p > 0.05$) in all time points. (Mean \pm SEM)

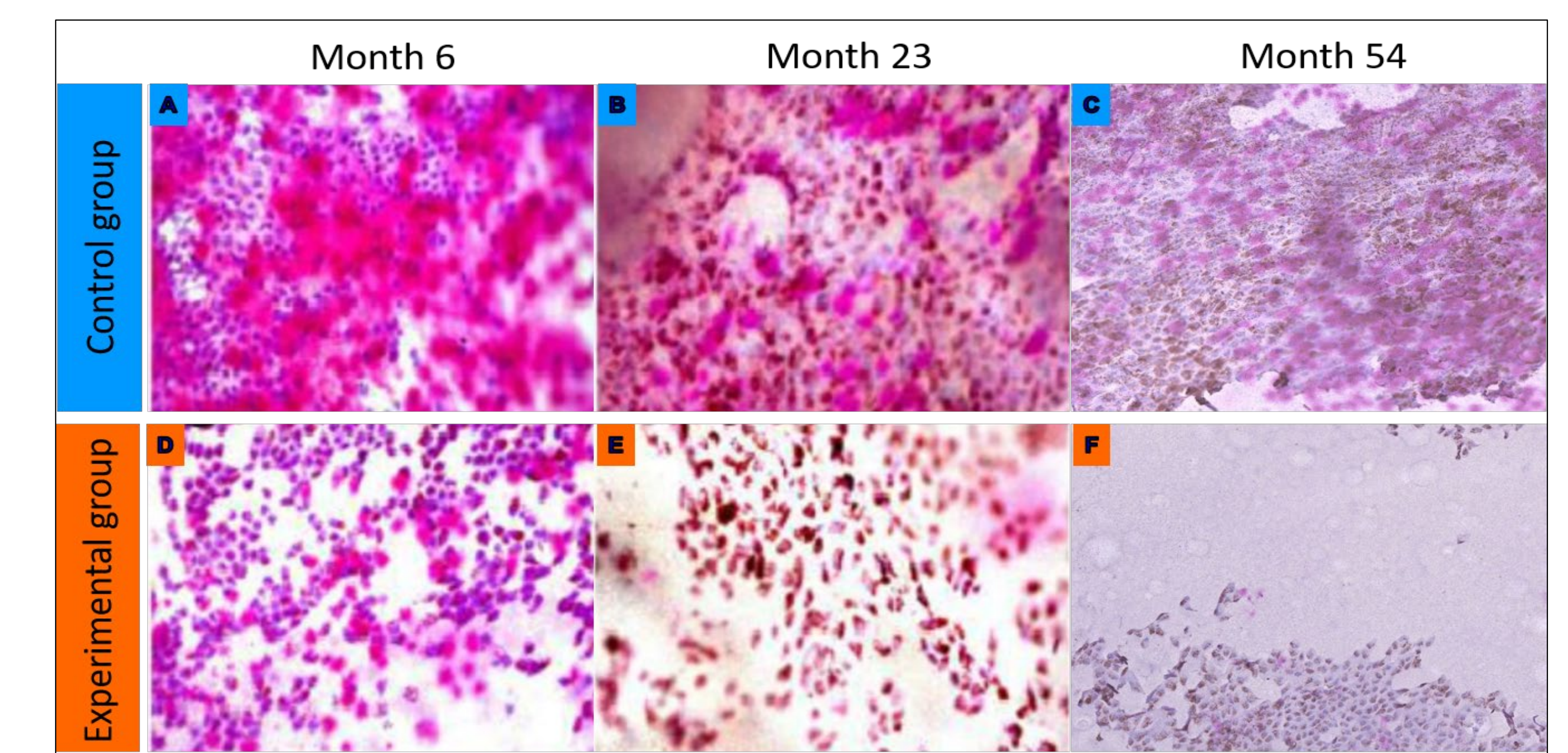


Figure 6. The conjunctival impression cytology indicated representative pathological changes such as decreased number of goblet cells and grade III Nelson's change in most of the conjunctival epithelial cells since M23 in experimental animals. The representative images (X400) were taken from the PAS staining samples in photo A, B, C (control group) and D, E, F (experimental group) at M6, M23, and M54, respectively.

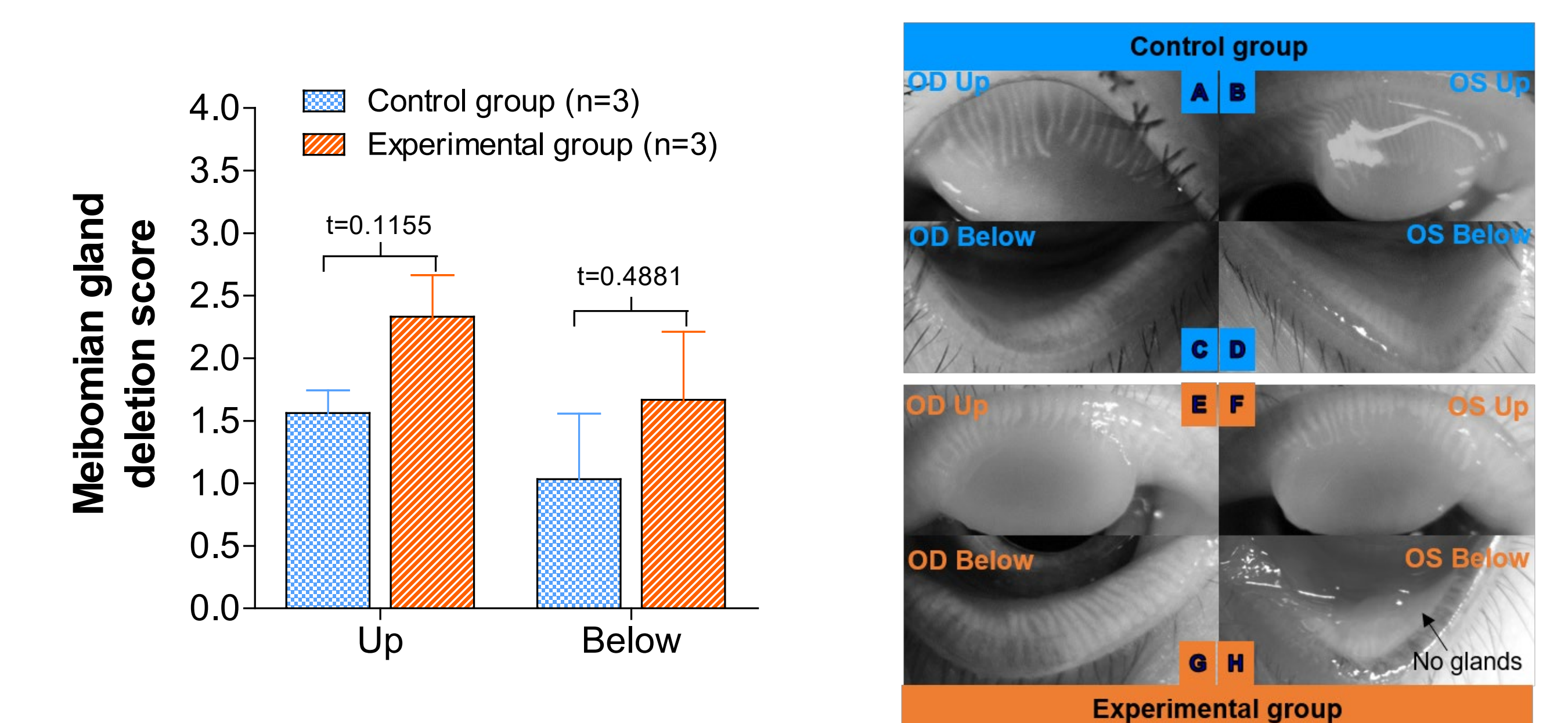


Figure 7 (left) & 8 (right). The meibomian gland deletion score in the experimental group was higher than that of control group but without significant difference at M54 ($p > 0.05$). The representative ocular images of the up and below meibomian gland were taken with infra-red light in photo A, B, C, D of a control group animal and in photo E, F, G, H of an experimental group animal at M54, respectively.